

Multimodality Neuroimaging in the Stanford ADRC

Beth Mormino, PhD
Assistant Professor
Department of Neurology & Neurological Sciences
Stanford School of Medicine

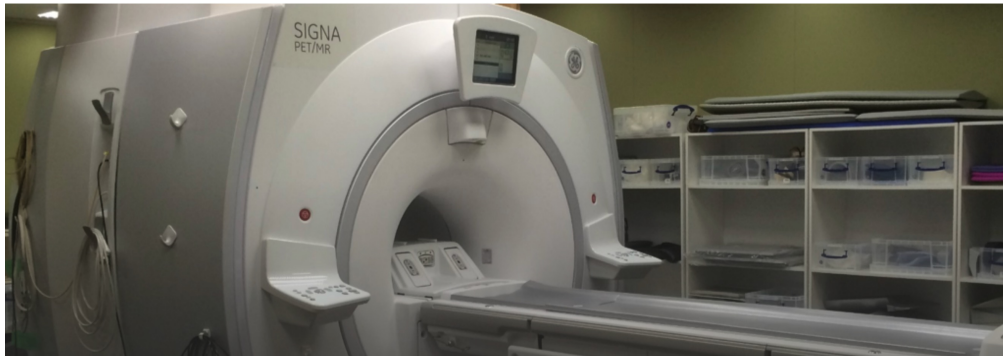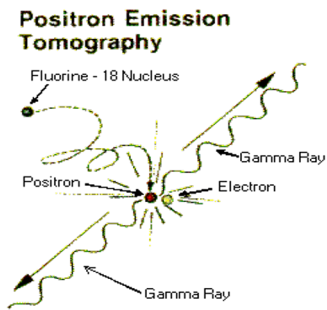
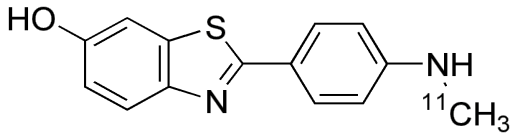
ADRC Participant Appreciation Day
Nov 2, 2022



Stanford ADRC Imaging Core

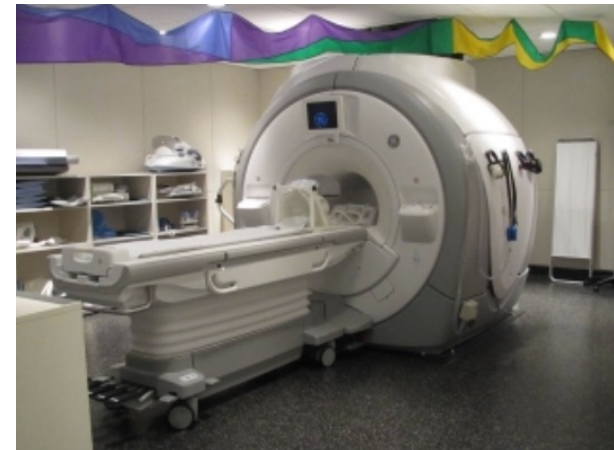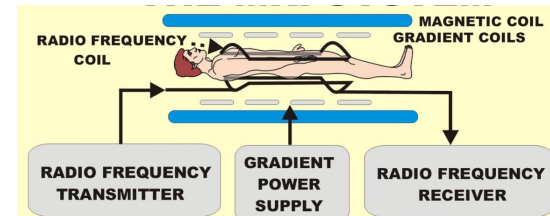


Positron Emission Tomography (PET)



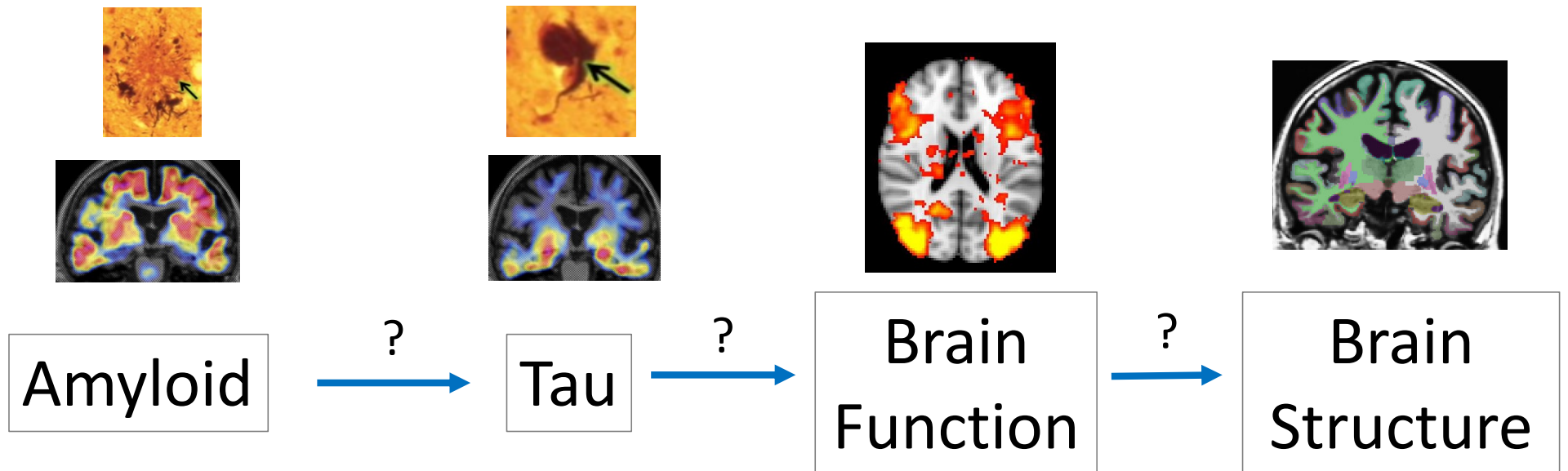
→ Specific target in brain
(amyloid plaques, tau tangle)

Magnetic Resonance Imaging (MRI)



→ Different tissue types
(brain function and structure)

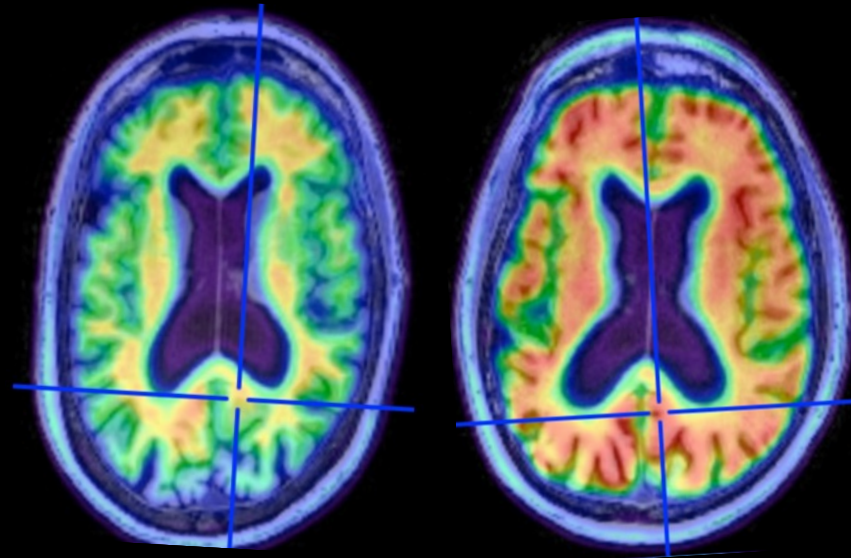
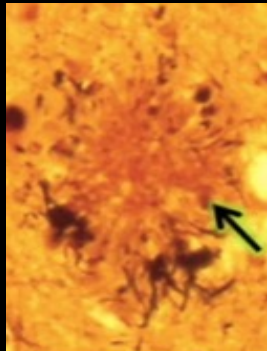
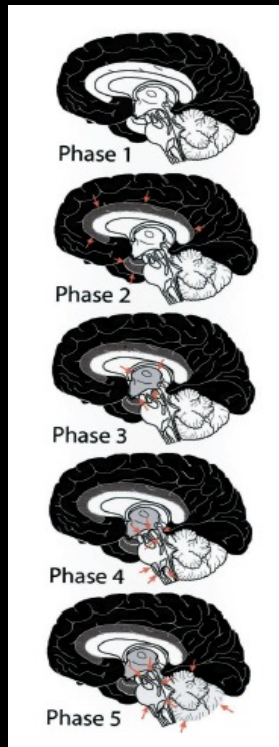
PET & MRI measures multiple targets



*Future...
Lewy Bodies? TDP-43?*

Amyloid PET

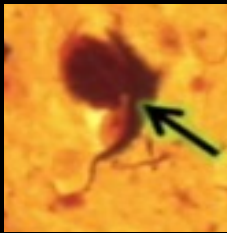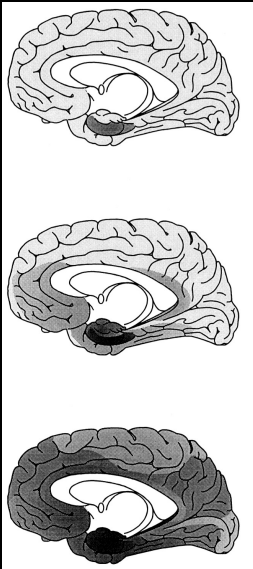
Amyloid Plaques



Thal 2002

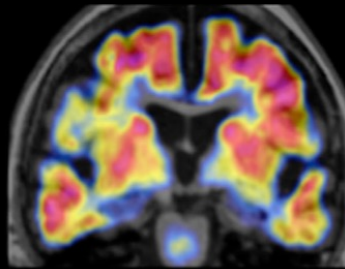
Tau PET

Tau Tangles

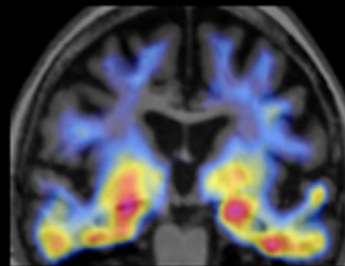


Braak & Braak 1997

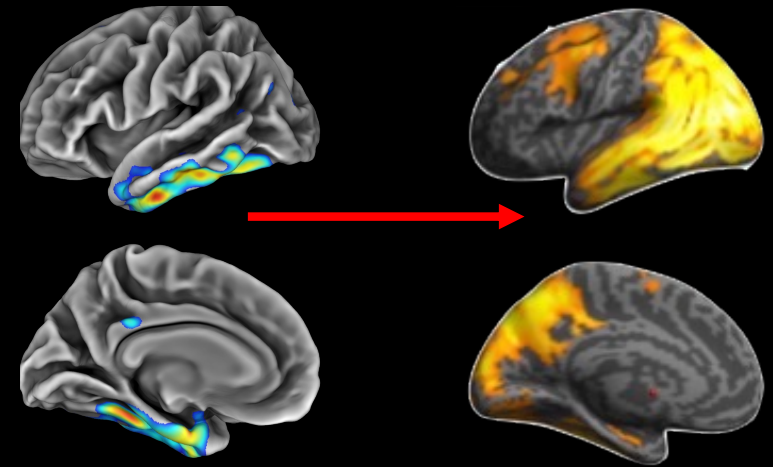
Amyloid Scan



Tau Scan

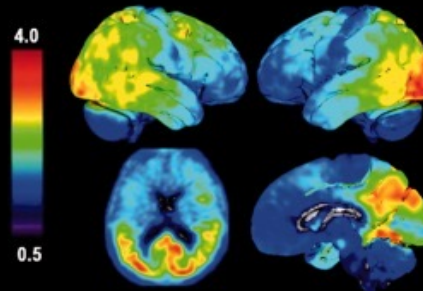


Focal to Widespread

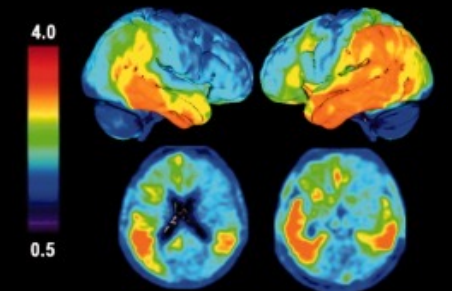


AD Subtypes

A Posterior cortical atrophy

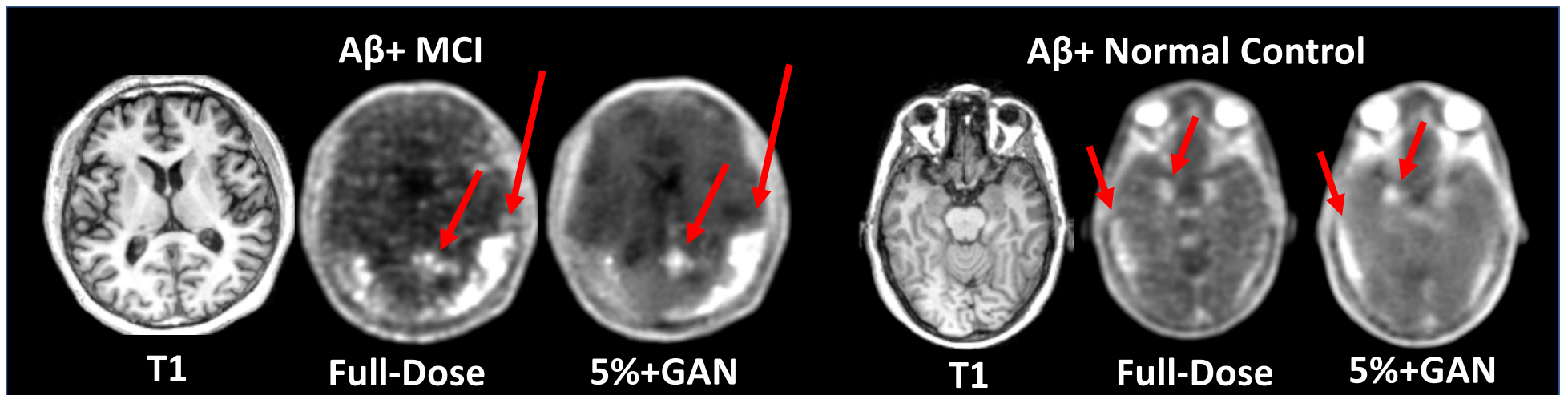


B Logopenic variant PPA



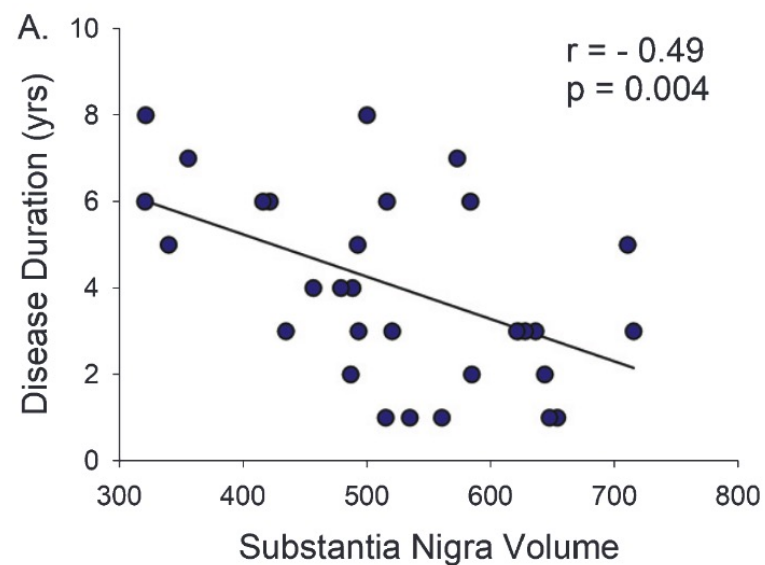
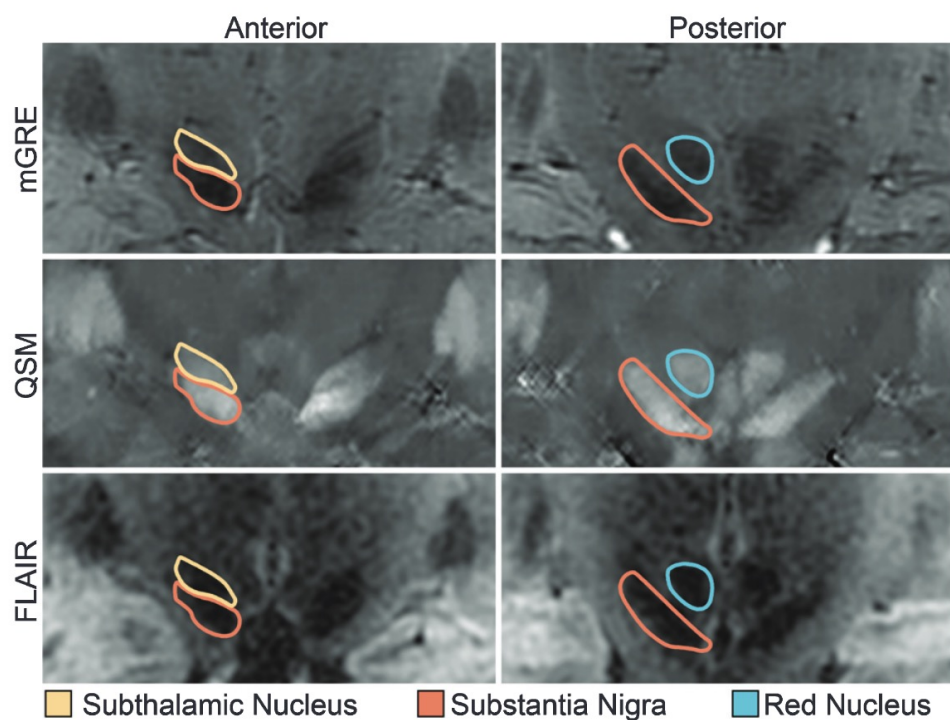
Ossenkoppele et al., 2016

Ultra-low-dose Tau PET Imaging (Zaharchuk)



7T MRI (Poston & Zeineh)

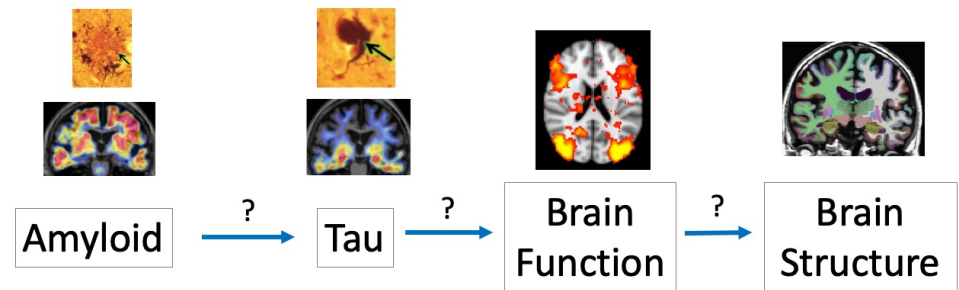
Substantia Nigra volume in Parkinson's



Poston & Zeineh 2020

Imaging Goals

- Combine PET and MRI markers
 - Risk profiles
 - Heterogeneity in trajectories
 - Validate blood markers



- Integrate advanced imaging modalities and methodology
 - Reduce barriers to imaging
 - Improve sensitivity

Thank you!



bmormino@stanford.edu